

TWO CONTRASTING PATIENTS GAIN FREEDOM FROM MEDICATIONS



The versatility of *ab interno* canaloplasty is demonstrated in a young, healthy patient and in another patient with cataracts and age-related macular degeneration.

BY I. PAUL SINGH, MD

The days of reserving surgery for advanced glaucoma cases—and opting for them only after exhausting all other treatment options—now seem like a distant memory. However, determining the best timing and the best MIGS procedure for each patient is still a malleable process, particularly for those of us who employ many different MIGS options. In these two cases, the primary goal was to get patients with controlled glaucoma off of medications. Although the two circumstances are very different, I chose *ab interno* canaloplasty with the iTrack (Nova Eye Medical) to maximize aqueous outflow through the conventional pathway with little destruction to the target tissues while reserving the ability to offer future surgical options for glaucoma.

CASE 1: A YOUNG, HEALTHY PHAKIC PATIENT

A healthy 54-year-old phakic woman with primary open-angle glaucoma was suffering because of her drops, and her ocular surface told the tale. She was using three topical medications every day: generic timolol once a day and nightly netarsudil 0.02% (Rhopressa, Aerie) and generic latanoprost 0.005%. This patient had early, preparametric glaucoma, with OCT showing some

TABLE 1. Case 1: Baseline examination findings

Ocular history	POAG diagnosed in 2009 SLT with moderate response in 2012 and 2013 Dissatisfied with drop therapy, complaints of fluctuating vision
BCVA	20/20 OU
Slit-lamp examination	1-2+ conjunctival injection 2+ corneal SPK No cataract
IOP	19-25 mm Hg OU Tmax = upper 20s
Pachymetry	542 µm OD, 535 µm OS
Hysteresis	9.2 OD, 8.7 OS
Fundus examination	0.7 c/d OU with GCC loss OS>OD Macula, vessels, and periphery were healthy
Visual Fields	Minimal loss
OCT	Early damage to GCC and RNFL (OS>OD)

Abbreviations: GCC, ganglion cell complex; OCT, optical coherence tomography; POAG, primary open-angle glaucoma; RNFL, retina nerve fiber layer; SLT, selective laser trabeculotomy; SPK, superficial punctate keratitis

early damage to the ganglion cell complex and the retinal nerve fiber layer (OS>OD) (Table 1 and Figure 1). However, the patient interview was telling: She asked me, “Do I have to take these drops forever?”

The slit-lamp examination showed 1-2+ conjunctival injection and 2+

corneal superficial punctate keratitis (SPK). From my perspective, when a patient is this unhappy taking drops and displaying all the signs and symptoms of ocular surface damage, I know she is unlikely to be adherent to her medications, which always concerns me. The patient also complained that her

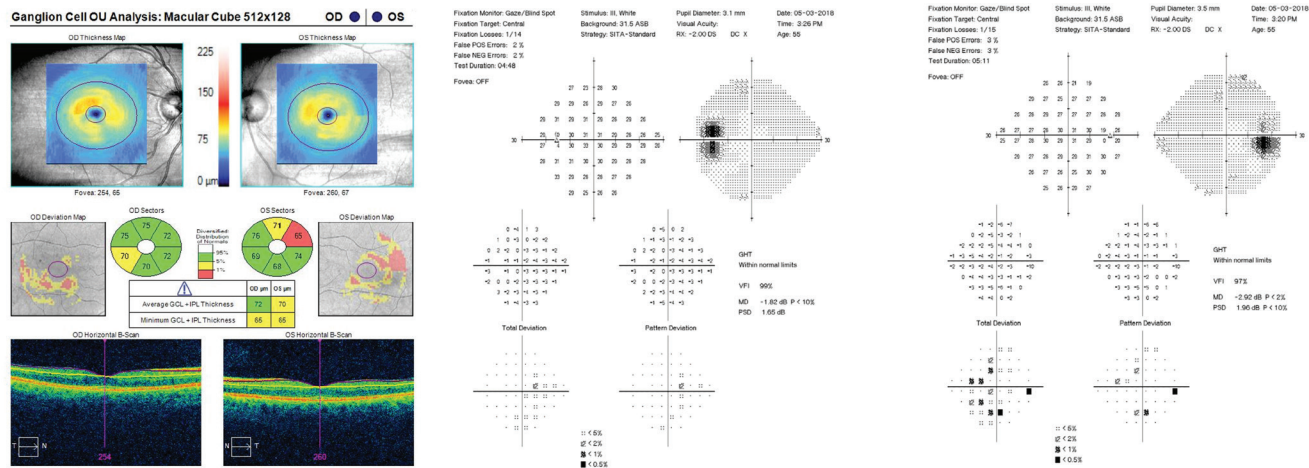


Figure 1. Although this patient had some early damage to the ganglion cell complex and the retinal nerve fiber layer, the primary motivation for surgical intervention was to reduce her medication burden.

vision fluctuated frequently, a problem studies have shown correlates with greater risk of glaucoma progression over time.^{1,2}

SURGERY AND RESULTS

This patient had early, preparametric glaucoma. If I hold off on an intervention in this type of case, the patient will likely continue to struggle with multiple medications, ocular surface problems, and almost certainly noncompliance, which puts her at risk for progressive visual field loss. She needed a procedure—it was just a matter of choosing her best option.

Because she was phakic and did not have a cataract, placing a stent was not an on-label option. I also did not want to cut or remove tissue with a proce-

TABLE 2. Case 1: Comparison of clinical parameters before and after *ab interno* canaloplasty with iTrack

	BASELINE/PREOP	POSTOP 1M	POSTOP 12M	POSTOP 24M
IOP	19-25 mm Hg	14 mm Hg	18 mm Hg	13 mm Hg
Glaucoma medications	3	0	0	1
Conjunctiva	1-2+ conjunctival injection	No injection	No injection	No injection
Corneal epitheliopathy	2+ SPK	1+ SPK	Min SPK	Min SPK

cedure like a goniotomy or gonioscopy-assisted transluminal trabeculotomy (GATT). Furthermore, preserving the trabecular meshwork would reserve the opportunity to use a stent later

if the patient developed cataracts. Because previous attempts with selective laser trabeculoplasty (SLT) did not deliver much improvement in pressure, I concluded the resistance might be distal to the trabecular meshwork, such as in the canal or distal outflow system. Based on these considerations, I determined that addressing multiple areas of resistance in the conventional pathway using *ab interno* canaloplasty with iTrack made the most sense.

The goals of surgery were to safely stabilize the patient's pressure with the least destruction possible and reduce or eliminate her topical medications. After *ab interno* canaloplasty with iTrack, she was medication-free for 1 year, with pressures in the mid-teens

"I ALSO DID NOT WANT TO CUT OR REMOVE TISSUE WITH A PROCEDURE LIKE A GONIOTOMY OR [GATT]. ... PRESERVING THE TRABECULAR MESHWORK WOULD RESERVE THE OPPORTUNITY TO USE A STENT LATER IF THE PATIENT DEVELOPED CATARACTS."

TABLE 3. Case 2: Baseline examination findings

Ocular history	POAG diagnosed 2001 1 ALT “many years before” (2006) 2 previous SLT with no response (2009, 2012) AMD OU diagnosed 2001 ERM OS Retinal tear (OS) Previous retinopexy
BCVA	20/30 OD, 20/50 OS
Slit-lamp examination	Mild conjunctival injection 1-2+ corneal SPK 3+ nuclear sclerotic cataract OD
IOP	18-21 mm Hg OU
Fundus examination	c/d: 0.75 OD, 0.8 OS Diffuse RNFL loss and PPA
Visual Fields	Report from referring optometrist: “stable for 3 years”
OCT	Macular degeneration (OS>OD)

Abbreviations: AMD, age-related macular degeneration; ALT, argon laser trabeculotomy; ERM, epiretinal membrane; GCC, ganglion cell complex; OCT, optical coherence tomography; POAG, primary open-angle glaucoma; PPA, peripapillary atrophy; RNFL, retinal nerve fiber layer; SLT, selective laser trabeculotomy; SPK, superficial punctate keratitis

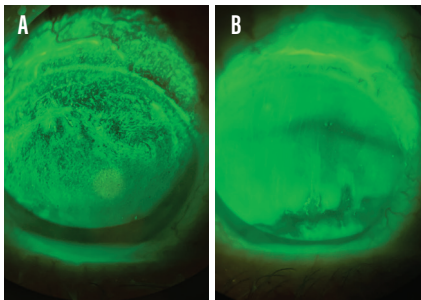


Figure 2. Corneal staining in the patient upon presentation (A) demonstrates damage to the ocular surface. After *ab interno* canaloplasty with iTrack was performed, IOP was controlled without need for medication, which led to resolution of ocular surface findings (B).

(Table 2). Pressures rose slightly after 1 year, so she was put on nightly bimatoprost 0.01% (Lumigan, Allergan). Two years later, her pressures remain under control. Once the patient came off the three-medication regimen, her corneal surface improved very quickly, and her complaints of fluctuating vision diminished. Overall, she was much happier and more comfortable, and I am confident that she can be compli-

ant with one nightly drop to manage her pressure. If and when cataract surgery is needed in the future, it may be possible for her to once again be completely free of medications if another MIGS procedure is performed.

CASE 2: PATIENT WITH CATARACT AND AGE-RELATED MACULAR DEGENERATION (AMD) MAXED ON MEDS

A 72-year-old cataract patient was maxed-out on glaucoma medications (Table 3). Her list of topical drops included bimatoprost 0.01% (Lumigan, Allergan) at bedtime, daily generic

SEE IT NOW

iTrack Ab Interno Canaloplasty: Surgical Technique

I. Paul Singh, MD, demonstrates the technique for external advancement of the catheter during *ab interno* canaloplasty with iTrack.

eyetu.be/pujedocuko

timolol, and twice daily brimonidine 0.1% (Alphagan P, Allergan) and cyclosporine (Restasis, Allergan). She was also taking aspirin therapy and clopidogrel (Plavix, Sanofi Aventis).

On slit-lamp exam, a 3+ nuclear sclerotic cataract was evident, and I could see mild conjunctival injection and 2+ corneal SPK with irregular epithelium. Corneal staining confirmed the clinical impression of damage to the ocular surface (Figure 2). She told me, “These drops are miserable. And I keep losing them!” Because the medications were making her so unhappy and it was hard for her to keep track of them, I knew she was unlikely to be fully compliant.

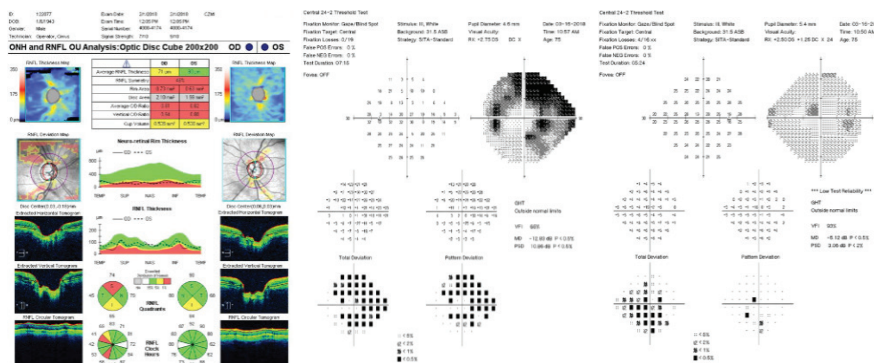
SURGERY AND RESULTS

Some of this patient’s field loss was related to the bilateral AMD and retinopexy in the left eye (Figure 3). For her cataract procedure, I focused on optimizing vision in her right eye first, implanting a monofocal IOL and performing YAG capsulotomy once a pos-

“THE FAILURE OF TWO ATTEMPTS WITH SLT TOLD ME THERE WAS RESISTANCE IN SCHLEMM CANAL OR BEHIND IT, NOT JUST IN THE TRABECULAR MESHWORK.”

TABLE 4. Case 2: Comparison of clinical parameters before and after *ab interno* canaloplasty with iTrack

	BASELINE/PREOP	POSTOP 1M	POSTOP 12M	POSTOP 24M
IOP	18-21 mm Hg	15 mm Hg	15 mm Hg	16 mm Hg
Glaucoma medications	3	0	0	0
Corneal epitheliopathy	1-2+ corneal SPK	1+ SPK	Min SPK	Min SPK

**Figure 3.** The patient had some visual field loss related to macular degeneration, particularly in the left eye. The functional deficit is mirrored by retina nerve fiber layer loss.

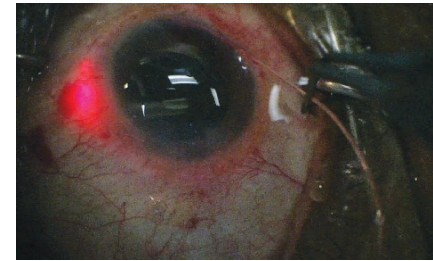
terior capsule opacification formed.

The goal for this patient's MIGS procedure was to get her IOP into the mid to upper teens so she could get off glaucoma medications. Although her fields and IOP were stable, I saw no reason for her to continue to struggle with managing multiple medications.

The failure of two attempts with SLT told me there was resistance in Schlemm canal or behind it, not just in the trabecular meshwork. If we flushed out the trabecular meshwork, Schlemm

canal, and distal channels using *ab interno* canaloplasty, we could address multiple points of potential resistance to outflow (Figure 4 and Video).

After surgery, the patient's visual acuity OD was 20/30 at 1 day and 20/20 at 1 week. We tapered a steroid over 4 weeks and kept her on a topical nonsteroidal antiinflammatory drug for 12 weeks. The optic nerve head was stable. Importantly, the patient was able to stop glaucoma medications completely and the slit lamp showed

**Figure 4.** During ABIC with iTrack, the catheter's lighted tip helps guide insertion and removal in Schlemm canal.

a quiet conjunctiva with mild corneal SPK (Figure 2 and Table 4). She told me her eyes felt much better, and that it was "so nice to stop the glaucoma drops." With her IOP in a healthy range and her ocular surface vastly improved, we were able to focus on her AMD instead of juggling multiple problems. This case is a good example of how *ab interno* canaloplasty, which yields minimal destruction to the ocular tissues, addresses multiple points of resistance and has tremendous power to improve IOP, and thus reduce patients' reliance on medications, in a complex case without introducing new challenges. ■

1. Baudouin C. Detrimental effect of preservatives in eyedrops: implications for the treatment of glaucoma. *Acta Ophthalmologica*. 2008;86(7):716-726.
2. Stringham J, Ashkenazy N, Galar A, Wellik SR. Barriers to glaucoma medication compliance among veterans: dry eye symptoms and anxiety disorders. *Eye Contact Lens*. 2018;44:50-54

I. PAUL SINGH, MD

- President, The Eye Centers of Racine and Kenosha in Wisconsin
- Member, *Glaucoma Today* Editorial Advisory Board
- ipsingh@amazingeye.com
- Financial disclosures: Aerie, Allergan, Glaukos, New World Medical, Nova Eye Medical,

IMPORTANT SAFETY INFORMATION

iTrack™ has a CE Mark (Conformité Européenne) and US Food and Drug Administration (FDA) 510(k) # K080067 for the treatment of open-angle glaucoma.

INDICATIONS: The iTrack™ canaloplasty microcatheter has been cleared for the indication of fluid infusion and aspiration during surgery, and for catheterization and viscodilation of Schlemm's canal to reduce intraocular pressure in adult patients with open-angle glaucoma.

CONTRAINDICATIONS: The iTrack™ canaloplasty microcatheter is not intended to be used for catheterization

and viscodilation of Schlemm's canal to reduce intraocular pressure in eyes of patients with the following conditions: neovascular glaucoma; angle closure glaucoma; and previous surgery with resultant scarring of Schlemm's canal.

ADVERSE EVENTS: Possible adverse events with the use of the iTrack™ canaloplasty microcatheter include, but are not limited to: hyphema, elevated IOP, Descemet's membrane detachment, shallow or at anterior chamber, hypotony, trabecular meshwork rupture, choroidal effusion, Peripheral Anterior Synechiae (PAS) and iris prolapse.

WARNINGS: The iTrack™ canaloplasty microcatheter is

intended for one time use only. DO NOT re-sterilize and/or reuse, as this can compromise device performance and increase the risk of cross contamination due to inappropriate reprocessing.

PRECAUTIONS: This iTrack™ canaloplasty microcatheter should be used only by physicians trained in ophthalmic surgery. Knowledge of surgical techniques, proper use of the surgical instruments, and post-operative patient management are considerations essential to a successful outcome.

www.glaucoma-iTrack.com

Sponsored by
NOVAEYE
MEDICAL